

1988 0003

Original

25 January 1965

SUBJECT: The Autopsy of President Kennedy. SUMMARY.

On the recommendation of Brigadier General Blumberg, Director of the Armed Forces Institute of Pathology and at the request of Commander Humes, MC, USN, Director of Laboratories, Naval Medical School. who called me at home by telephone, I went to the National Naval Medical Center, Bethesda, Maryland, where I arrived at approximately 2030 hours on 22 November 1963. The autopsy of President Kennedy was in progress. The radiologist had studied the radiographs of the head revealing numerous small metallic fragments.

I examined the wounds. The scalp of the back of the head showed a small laceration, 15 X 6 mm. Corresponding to this lesion, I found a through-and-through wound of the occipital bone, with a crater visible from the inside of the cranial cavity. This bone wound showed no crater when viewed from outside the skull. On the basis of this pattern of the occipital bone perforation, I stated that the wound in the back of the head was an entrance. Later in the evening, I examined three bone fragments sent from Dallas and corresponding to the large head wound approximately 130 mm. in diameter in the right side of the cranial vault. After identifying their anatomic external and internal surfaces, I noticed that the beveling of the fragments was apparent when viewed from outside. I stated then that these portions of bone were part of a wound of exit. Therefore, the large irregular wound in the right side of the cranial vault was a wound of exit.

The wound in the upper back of the President, to the right of the mid-line was oval and had a regular, soiled inverted margin. I stated that this was an entrance. My attempt to probe the path of the bullet was unsuccessful. I examined the tracheotomy skin wound and the trachea and did not find evidence of a bullet wound. Having a wound of entrance in the back and no corresponding exit, I requested a whole body radiographic survey, the results of which were negative. There was no bullet in the President's cadaver except the metallic fragments seen in the head. It was only after the autopsy that the prosecutors learned, thanks to a telephone call of Cdr. Humes to Dallas, that the small wound of exit in the front of the neck had been extended by the Dallas surgeons at the time of their tracheotomy.

Return to

MD 28

000327

(1)

I testified before the Warren Commission on 16 March 1964. Chief Justice Warren swore me in. The Commission admitted as Exhibit 400 the schematic representation of a perforating missile wound of the skull that I had prepared for teaching purposes at the Armed Forces Institute of Pathology before the assassination.

When the "Warren Report" became public on 28 September 1964, I learned that independent experiments made without my knowledge at the U. S. Army Arsenal, Edgewood, Maryland with the 6.5-mm. rifle of Lee Harvey Oswald and ammunition similar to that of the assassination, had confirmed my opinion regarding the perforating wound of the head and the entrance wound of the back.

Pierre A. Finck

PIERRE A. FINCK 04 043 322
Lt. Colonel, MC, USA
Chief, Military Environmental
Pathology Division, and
Chief, Wound Ballistics Pathology
Branch
Armed Forces Institute of Pathology
Washington, D. C. 20305

Quoted

W. S. C. C. C.
3 Feb '65

000328

(2)

OTIS HISTORICAL ARCHIVES
NATIONAL MUSEUM OF HEALTH AND MEDICINE
ARMED FORCES INSTITUTE OF PATHOLOGY

1 February 1965

SUBJECT : Personal notes on the Assassination of President Kennedy.

TO : Brig. Gen. J. M. Blumberg, MC, USA
The Director
Armed Forces Institute of Pathology
Washington, DC 20305

1. In compliance with your request, attached are Subject notes.
2. Before the "Warren Report" was published, in September 1964, I received Directives by telephone, from the White House, through your Office and through the Naval Medical School in Bethesda, not to discuss Subject autopsy beyond the contents of the Warren Report.
3. I wish to take this opportunity to thank you for the confidence you have shown in my behalf by giving my name to Cdr. Humes, appointing me as representative of your Institute in the autopsy of President Kennedy.

Pierre A. Finck

Lt. Colonel Pierre A. FINCK, MC, USA
Chief, Military Environmental Pathology Division &
Chief, Wound Ballistics Pathology Branch
Armed Forces Institute of Pathology
Washington, DC 20305

000329

3

THE AUTOPSY OF PRESIDENT KENNEDY

by Lt. Colonel Pierre A. FINCK, MC, USA.

Commander Humes, MC, USN, Director of Laboratories, Naval Medical School, National Naval Medical Center, Bethesda, Maryland, called me at home by telephone on 22 Nov 1963, 2000 hours. He told me to go immediately to the Naval Hospital. Brigadier General Blumberg, MC, USA, of the Armed Forces Institute of Pathology, Washington, D. C., had given my name.

I arrived at the Naval Hospital at 2030 hours. I saw a helicopter on the ground. A seaman escorted me to the autopsy room, guarded outside by military personnel and inside by Agents of the U. S. Secret Service. Rear Admiral Galloway, Commanding the Naval Center, Cdr Humes and Cdr Boswell, MC, USN, Chief of Pathology, showed me the wounds in the President's head. The brain, the heart and the lungs had been removed before my arrival. X ray films of the head and chest had been taken.

Also present in the autopsy room were : Rear Admiral Kenney, Surgeon General of the Navy; Rear Admiral Burkley, White House Physician; one Army Major General; a Brigadier General, Air Force Aid to the President; Capt Stover, MC, USN, Commanding the Naval Medical School; Capt Osborne, MC, USN, Chief of Surgery; Cdr Ebersole, MC, USN, a radiologist; a Navy photographer; Navy officers and enlisted men; Agents of the U. S. Secret Service and Federal Bureau of Investigation (FBI).

The Autopsy number assigned ~~xx~~ to the President by the Naval Hospital was :
A - 63 - 272.

000330

4

THE WOUNDS

The scalp of the vertex is lacerated. There is an open comminuted fracture of the cranial vault, many portions of which are missing.

The autopsy had been in progress for thirty minutes when I arrived.

Cdr Humes told me that he only had to prolong the lacerations of the scalp before removing the brain. No sawing of the skull was necessary.

The opening of the large head wound, in the right fronto-parieto-occipital region, is 130 millimeters (mm) in diameter.

I also noticed another scalp wound, possibly of entrance, in the right occipital region, lacerated and transversal, 15 x 6 mm. Corresponding to that wound, the skull shows a portion of a crater, the beveling of which is obvious on the internal aspect of the bone; on that basis, I told the prosecutors and Admiral Galloway that this occipital wound is a wound of ENTRANCE. No EXIT wound is identifiable at this time in the skull, but close to midnight, portions of cranial vault ~~fragments~~ are received from DALLAS, Texas. X ray films of these bone specimens reveal numerous metallic fragments. Two of the bone specimens, 50 mm in diameter, reveal BEVELING when viewed from the external aspect, thus indicating a wound of EXIT. Most probably, these bone specimens are part of the very large right skull wound, 130 mm in diameter and mentioned above. This right fronto-parieto-occipital wound is therefore an EXIT.

There is another wound, in the region of the right trapezius muscle, at 140 mm from the right acromion and at 140 mm from the tip of the right mastoid process (I took these measurements). The wound is OVAL, 7 x 4 mm, and shows well demarcated edges.

This wound cannot be probed with the soft probe available. There is subpleural hemorrhage in the right apical mesial region. The apex of the right lung is hemorrhagic, without laceration of the pleura.

On the basis that there is a wound possibly of entrance, which cannot be probed through the body, I SUGGEST X RAY FILMS BE TAKEN, ANTEROPOSTERIOR AND LATERAL, OF THE ENTIRE BODY, BEFORE GOING ANY FURTHER WITH THE AUTOPSY. This radiologic survey does not reveal any major missile in the President's cadaver. There are only numerous metallic fragments in the head, in the sagittal ~~xxx~~ plane. Some of these are recovered and are turned over to FBI Agents against receipt. I help the Navy photographer to take photographs of the occipital wound (external and internal aspects) as well as of the wound in the back.

There is a recent TRACHEOTOMY wound (transversal incision) with moderate hemorrhage in the subcutaneous tissue. Thanks to a telephone call from Cdr Humes to Dallas, I found out later that the surgeons in Dallas had EXTENDED THE EXIT WOUND in the anterior aspect of the neck to make his tracheotomy. The tracheotomy wound was examined by the three prosectors. None of us noticed a bullet wound along its course. THE ORGANS OF THE NECK WERE NOT REMOVED : THE PRESIDENT'S FAMILY INSISTED TO HAVE ONLY THE HEAD EXAMINED. Later, the permission was extended to the CHEST.

Three civilian embalmers from GAWLER FUNERAL HOME prepared the body for burial. It took four hours to clean, embalm and dress the body of the President. The cadaver left the Naval Hospital at 0400 hours, 23 November 1963, in a casket of African mahogany. The officers present saluted the casket, covered with a flag.

After the body was placed into a USN ambulance, to be brought to the White House I saw Mrs Jacqueline Kennedy come out of the hospital and get into her car, protected by the Secret Service. She had the same pink dress she was wearing in Dallas at the time of the assassination.

On Sunday 24 November 1963, I went to the Naval Hospital to help Cdr Humes who had written an autopsy report. Humes, Boswell and Finck, the three prosecutors, signed the Autopsy report in the Office of Admiral Galloway. ^{convince Humes agt} (I had suggested several corrections in the autopsy report. ~~_____~~ While we were checking the autopsy report in the Admiral's office, the Television announced the murder of Oswald by Ruby).

In my discussion with Cdr Humes, I stated that we should not check the block " complete Autopsy " in the Autopsy Report Form. In compliance with the wishes of the Kennedy family, the prosecutors had confined their examination to the head and chest. Humes declared that the block " complete Autopsy " should be checked.

Cdr Humes called me on 29 Nov 63 that the three prosecutors would examine the brain at the Naval Hospital. I asked if a representative of the Neuropathology Branch of the Armed Forces Institute of Pathology would be invited to the gross examination of the brain. Humes told me that no additional persons would be admitted. Humes, Boswell and myself examined the formalin fixed brain. A US Navy photographer was present.

DESCRIPTION : The formalin fixed brain weighs 1500 grams. The arteries of the base show no arteriosclerotic plaques. The left hemisphere shows minimal frontal and parietal subarachnoid hemorrhage.

7

000333

There is a parasagittal laceration of the right cerebral hemisphere, extending from the frontal to the occipital lobes and exposing the Thalamus.

The Corpus Callosum is lacerated. No metallic fragments are identified but there are numerous small bone fragments, between one and ten millimeters in greatest dimension, in the container where the brain was fixed.

The CONVOLUTIONS of the brain are flat and the SULCI are narrow, but this is interpreted as a fixation artefact because the change was not observed at the time of autopsy.

COLOR AND BLACK AND WHITE PHOTOGRAPHS are taken by the US Navy photographer : superior and inferior aspects of the brain.

Cdr Humes takes SECTIONS from the subarachnoid hemorrhage of the left cerebral hemisphere and from the laceration of the right cerebral hemisphere but does not ~~make~~ make coronal sections in order to preserve the specimen.

On 13 Dec 1963, I had the opportunity to examine the weapon used to kill President Kennedy. I saw the 6.5 mm Carcano Italian Short Rifle in the Firearms Unit of the Federal Bureau of Investigation (FBI Laboratory).

000334

8

The President's Commission on the
Assassination of President Kennedy
(" Warren Commission ")

000335

9

THE WARREN COMMISSION

On 16 March 1964, I went to the Veterans of Foreign Wars (VFW) Building, 200 Maryland Avenue NE, Washington, DC, with Humes and Boswell, to appear before the Warren Commission. We reported at 1100 hours to Mr Arlen Specter, Attorney at Law from Philadelphia, who was Counsel to the Warren Commission appointed by President Johnson to investigate the assassination of Kennedy.

Mr Specter told us that the Attorney General, Robert Kennedy, brother of the assassinated President, did not make available to the Commission the X Ray films and the Photographs taken before and during the autopsy. I had seen the X ray films in the Autopsy room of the Bethesda Naval Hospital. The autopsy photographs, taken before and during the ~~xx~~ autopsy were turned over to the US Secret Service in the autopsy room and none of the prosecutors ever saw the processed photographs.

Mr Specter showed us the CLOTHING ~~were~~ worn by the President, the bullet recovered from the str^etcher of Governor Connally and two fragments of bullets, all showing a copper jacket and all fired by Oswald's rifle. I also had the opportunity to see the ballistics report & addressed by J Edgar HOOVER, FBI Director to the President of the Commission, dated 11 March 1964.

10

000336

CLOTHING : There is a hole in the back ~~in~~ of the President's coat, a portion of which ~~was~~ was removed by the FBI Laboratory for fibers study. The hole is approximately 15 cm below the upper ~~edge~~ edge of the collar to the right. Another hole is found immediately below the collar taken by the FBI Lab agents, for fiber control study.

The shirt of the President, white with brown stripes, and a Park Avenue shirt shop label, showed abundant blood in the back and front. There is a bullet hole, in the back and to the right, at 15 cm from the upper edge of the collar.

Immediately below the upper button of the front is a bullet hole perforating both ~~fl~~ flaps of the shirt, right and left. There is dry blood on the margins of both holes. The innermost hole reveals fibers directed outward, which indicates an EXIT PERFORATION. The ~~outer~~ outermost hole also shows this outward orientation of the ~~shirt~~ bloody shirt fibers, but to a lesser extent. These two anterior holes below the collar button correspond to the exit wound found by the Dallas surgeons at Parkland Hospital and which was extended for tracheotomy purposes. Dallas records show that the trachea had been lacerated by the bullet. WE DID NOT HAVE THIS INFORMATION AT THE TIME OF AUTOPSY.

The TIE worn by Kennedy, a blue silk tie labeled " Monsieur " Christian Dior, shows a tear of the cloth to the left side of the knot and corresponding to the two anterior holes in the shirt. The tie knot was not perforated but GLANCED by the bullet, which is indicated by the fact that the white padding of the tie is visible and that the blue cloth on the internal aspect of the knot is intact, which indicates a tangential path on the left side in relation to the knot.

000337

11

BALLISTICS REPORT FROM FBI : Ammunition used by Oswald is 6.5-mm
Mannlicher-Carcano copper jacketed bullet, made by Western Cartridge Co.
Bullet weight : approximately 160 grains. Muzzle velocity approximately
2100 feet per second, kinetic energy approximately 1600 foot-pounds.

FBI Report on CLOTHING : Perforations of the shirt in the anterior
portion below the collar button are typical for an EXIT WOUND.

My EXAMINATION OF THE MISSILES :

1. One copper jacketed bullet, consistent with 6.5 mm caliber.
Approximate length : 30 mm. I was told not to touch these missiles because
the FBI wanted to run more tests. The bullet shows rifle markings with twist
to the right. The bullet is fully jacketed and kept its original shape :
round nose and parallel edges. There is only one area of discoloration of the
jacket on the nose, showing a questionably flattened area, possibly
corresponding to impact with some hard surface.
2. One portion of distorted copper jacket, approximately 20 mm in diameter.
3. One portion of copper jacketed bullet, approximately 6.5 mm in diameter.

MEMBERS OF THE PRESIDENT'S COMMISSION PRESENT IN THE ROOM
at the time of my testimony :

Chief Justice Earl Warren, age 72.

Allen Dulles, 70, former Director of the Central Intelligence Agency.

J.S. Cooper, 62, Republican senator from Kentucky.

G. Ford, 50, Republican ~~Representative~~ Representative from Michigan.

J.J. McCloy, 68, one time US High Commissioner in West Germany.

MY TESTIMONY :

Chairman

I was sworn in by Earl Warren, President of the Commission.

My testimony lasted for thirty minutes.

I testified that Kennedy was shot from behind.

One bullet entered the back at 14 cm from the right acromion and at 14 cm from the right mastoid process, produced ecchymosis of the dome of the parietal pleura on the right and came out in the anterior neck below the larynx without injuring bones. X ray films had ruled ~~that~~ out bone injuries along the bullet path.

Another bullet struck Kennedy in the back of the head, at 25 mm to the of the external occipital protuberance and slightly above. The bullet produced many fragments and an exit wound of ~~130~~ 130 mm in the right temporo-parieto-occipital bone. Many metallic fragments were seen on X ray films but only ~~one was~~ ^{two were} recovered in the right frontal cerebral hemisphere, ^(approximately) and black, representing ~~at the most~~ one tenth of the bullet mass.

These fragments measured 7 X 2 and 3 X 1 mm.

000339

13

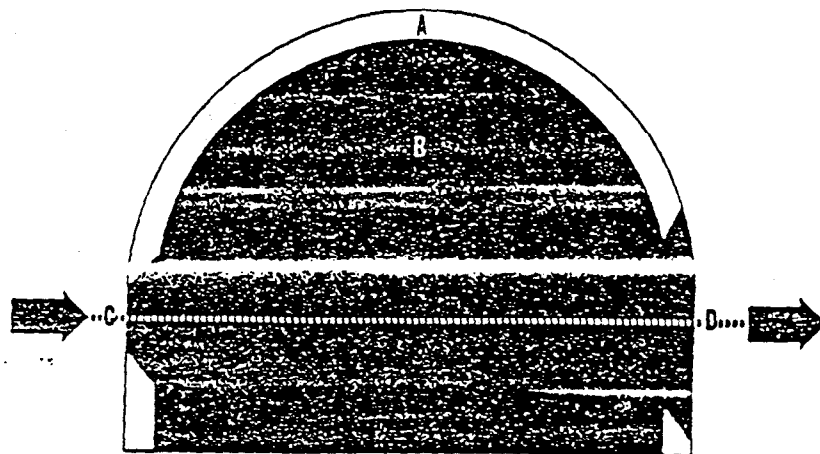
I explained to the Commission on what basis I could identify ENTRY and EXIT wounds in the skull. I brought with me a scheme I had prepared before the Assassination of Kennedy. I had been working on this diagram for three years, on and off, bringing modifications and simplifications to it. This diagram applies to bones as well as to a pane of glass or ^{panel of} wood. My scheme was admitted by Chief Justice Warren as Exhibit 400 of the Commission. (A copy is attached).

I also testified that, in my opinion, the oval wound in the right posterior superior aspect of the chest of Kennedy was an ENTRY. The edges were fairly regular and there was black fouling of the edges.

(14)

000340

PERFORATING MISSILE WOUND OF THE SKULL



A = Cranial vault. B = Cranial cavity. C = Entrance. D = Exit.

Arrows indicate missile path.

Entrance is often smaller than exit because of bullet "mushrooming" or tumbling and/or secondary missiles. Note "coning," "cratering," or "beveling" of the bone.

The diameter of the hole is smaller on the impact side. (The same differences of diameter apply to a glass pane.)

(Scheme by Scientific Illustration Division, AFIP, from data provided by Lt Col Pierre A. Finck, MC, USA. AFIP Neg. 63-4625.)

Scheme prepared before the assassination of Kennedy,
for teaching purposes.

Admitted as Commission Exhibit No. 400,
by Chief Justice Earl Warren, on 16 March 1964.

Reproduced in Volume XVII, page 50, of
HEARINGS before the President's Commission on the
Assassination of President Kennedy.

000341

15

On 16 March 1964, I also had the opportunity to examine COLOR PRINTS, approximately 10 X 20 cm, stamped " US Secret Service, Washington, DC satisfactory on the back and made from the only color film taken at the time of the Assassination of Kennedy. An amateur had taken for a g few seconds the scene of the murder and sold it to LIFE MAGAZINE ~~for \$40,000.~~ COLOR PRINTS, made from mm color picture, clearly show how Kennedy slumped forward from a sitting position in the Presidential car. The last frame does not show Kennedy, completely slumped forward but his wife, Jacqueline Kennedy, climbing on the trunk of the car (a Lincoln, made by the Ford Motor Company), seeking help for her husband. This sequence of photographs is compatible with a bullet hitting Kennedy in the back and with another bullet striking him in the head, both from behind.

On 16 March 1964, I had spent approximately seven hours with the WARREN COMMISSION.

000342

16

On 23 March 1964, I learned from an FBI Agent that the Warren Commission had asked the FBI to keep all the Exhibits of the Commission, due to lack of storage facilities on the floor occupied by the Commission in the VFW Building. The agent told me that he was in possession of the drawings made in two days by a US Navy enlistee^{el} man at the National Naval Medical Center, before the testimony of the prosecutors and showing the wounds of Kennedy. He also had Commission Exhibit 400, the scheme demonstrating a perforating missile wound of the skull, that I had submitted to the Commission.

All evidence and related material connected with Kennedy's Assassination and kept by the Firearms Unit of the FBI Laboratory occupied four cabinets, each 77 X 36 X 18 inches (195 X 91 X 45 centimeters).

The shirt of Texas Governor Connally also showed a hole in the right cuff.

(I did not have the opportunity to make exact measurements of these hole in the clothing of Connally. I wrote this description from memory, within two hours following my return from the Commission).

I also examined the REPLICA of the 6.5-mm Italian short rifle that killed Kennedy. Attached to the rifle was a Japanese optical device, magnifying four times and similar to the one used by Oswald.

The FBI made an excellent small scale reproduction of the buildings of Dallas, representing the scene of the assassination.

On 14 April 1964, I appeared again before the Warren Commission for a hearing. I spent five hours at the Veterans of Foreign Wars Building, 200 Maryland Avenue, NE.

INDIVIDUALS PRESENT were : Mr Specter, Mr Rankin, Mr Eisenberg, Counsels of the Commission; FBI and Secret Service Agents; Cdrs Humes and Boswell; Drs F.W. Light and Olivier, from the US Army Arsenal, Edgewood, Md.

I saw a copy of the 8 millimeter ~~movie~~ color motion picture film taken by an amateur and sold to LIFE magazine ~~for \$40,000.~~ ^{for \$40,000.} (1)

I saw the movie several times, at 18 frames per second and at slow motion. I also saw the 35 millimeter color lantern slides made from this movie, frame by frame. The movie and the slides show the President slumping forward after being hit in the back. Then it seems that Governor Connally has a spastic expression on his face, as he had been hit. His thigh is not visible and there is no evidence that blood appeared on his ~~xxxxxx~~ injured right wrist. THEN CAME THE SHOT THROUGH KENNEDY'S HEAD.

I had the opportunity to examine the clothing of Governor Connally. The Governor was scheduled to come to Washington during April, we were told. The COAT showed one hole in the back, on the right, at mid-distance between the upper edge and the lower edge of the right shoulder seem, close to the seem, at approximately 20 centimeters from the upper edge of the collar. One hole in the right anterior portion, at approximately 30 cm from the collar. One hole in the anterior edge of the x right wrist. The TROUSERS revealed one hole in the anterior portion of the knee. The SHIRT disclosed dry brown discoloration, probably blood. We were told that the shirt was sent to a Texan Senator, and had been cleaned and pressed being before being submitted to the Investigators. Holes in back and front were larger than in coat. Some holes seemed to have been enlarged by scissors cuts.

000345

19

SUMMARY

by Lt. Col. Finck

20

000346

SUMMARY

On the recommendation of Brigadier General Blumberg, Director of the Armed Forces Institute of Pathology and at the request of Commander Humes, MC, USN, Director of Laboratories, Naval Medical School, who called me at home by telephone, I went to the National Naval Medical Center, Bethesda, Maryland, where I arrived at approximately ²⁰³⁰~~2000~~ hours on 22 November 1963. The autopsy of President Kennedy was in progress. The radiologist had studied the radiographs of the head revealing numerous small metallic fragments.

I examined the wounds. The scalp of the back of the head showed a small laceration, 15 X 6 mm. Corresponding to this lesion I found a through-and-through wound of the occipital bone, with a crater visible from the inside of the cranial cavity. This bone wound showed no crater when viewed from outside the skull. On the basis of this pattern of the occipital bone perforation, I stated that the wound in the back of the head was an entrance. Later in the evening, I examined three bone fragments sent from Dallas and corresponding to the large head wound approximately 130 mm. in diameter in the right side of the cranial vault. After identifying their anatomic external and internal surfaces, I noticed that the beveling of the fragments was apparent when viewed from outside. I stated then that these portions of bone were part of a wound of exit. Therefore, the large irregular wound in the right side of the cranial vault was a wound of exit.

000347

21

The wound in the upper back of the President, to the right of the mid-line was oval and had a regular, soiled inverted margin. I stated that this was an entrance. My attempt to probe the path of the bullet was unsuccessful. I examined the tracheotomy skin wound and the trachea and did not find evidence of a bullet wound. Having a wound of entrance in the back and no corresponding exit, I requested a whole body radiographic survey, the results of which were negative. There was no bullet in the President's cadaver except the metallic fragments seen in the head. It was only after the autopsy that the prosecutors learned, thanks to a telephone call of Cdr. Humes to Dallas, that the small wound of exit in the front of the neck had been extended by the Dallas surgeons at the time of their tracheotomy.

I testified before the Warren Commission on 16 March 1964. Chief Justice Warren swore me in. The Commission admitted as Exhibit 400 the schematic representation of a perforating missile wound of the skull that I had prepared for teaching purposes at the Armed Forces Institute of Pathology before the assassination.

When the "Warren Report" became public on 28 September 1964, I learned that independent experiments made without my knowledge at the U. S. Army Arsenal, Edgewood, Maryland with the 6.5-mm. rifle of Lee Harvey Oswald and ammunition similar to that of the assassination, had confirmed my opinion regarding the perforating wound of the head and the entrance wound of the back.

After the publication of the Warren Report, numerous physicians criticized the autopsy protocol that did not describe the adrenal glands of Kennedy who suffered from adrenal insufficiency. The prosecutors complied with the autopsy permit and its restrictions. I was told that the Kennedy family first authorized the autopsy of the head only and then extended the permission to the chest. Organs of the neck were not removed because of the same restrictions. I feel that the prosecutors accomplished their MISSION that was to determine the direction of the shots and the cause of death. The head wound was definitely fatal. There were ~~xxx~~ rumor - and even testimonies - that the President had been shot from behind and from the front. I established that Kennedy had two wounds of entrance in back : one in the back of his head and one in his upper back at the base of the neck. After the completion ~~xxx~~ of the post mortem examination, the Surgeon General of the Navy told us not to discuss the autopsy with anyone even among prosecutors or with the investigators involved.

I was denied the opportunity to examine the clothing of Kennedy. ~~One officer who outbroke me told me that my request was only of academic interest. The same officer did not agree not to state that in the autopsy report that the autopsy was incomplete, as I had suggested to indicate~~

I saw the clothing of Kennedy, for the first time, on 16 March 1964, at the Warren Commission, before my testimony, more than three months after the autopsy.

I saw the x-ray films of the body but I never saw the photographs of the wounds that I had helped to take. They were turned over to the U. S. Secret Service. Agents of the Federal Bureau of Investigation took custody of the two metallic fragments recovered from the cerebral cortex.

Despite the incomplete or the inaccurate information we had at the time of the autopsy (for example, we were told that a bullet had been found on Kennedy's stretcher whereas it was on Connally's), the autopsy conclusions were verified by other examinations, such as gross, microscopic and spectrographic study of the clothing (FBI), and by independent experiments such as those conducted by scientists in Wound Ballistics at the U. S. Army Arsenal, Edgewood, Maryland.

More details are available in the Report of the President's Commission on the Assassination of President Kennedy (" Warren Report ") and in the 26 volumes of hearings and testimonies, all published by the U. S. Government Printing Office. See Mail Order Forms attached.

Pierre A. Finck

Lt. Colonel Pierre A. FINCK, MC, USA
04 043 322
Chief, Military Environmental Pathology Division and
Chief, Wound Ballistics Pathology Branch
ARMED FORCES INSTITUTE OF PATHOLOGY
Washington, D.C.

000350

24

COMMENT:

From the viewpoint of wound ballistics, the assassination of President Kennedy illustrates the role of the tissue in the wounding power of a projectile.

The first bullet that struck Kennedy in the back at a distance of approximately 180 feet (55 meters) and came out in the anterior portion of his neck did not strike bone and did not disintegrate.

The second bullet that struck Kennedy in the back of the head at a distance of approximately 270 feet (82 meters) disintegrated into numerous metallic fragments.

The two bullets were within the same range of kinetic energy. The muzzle energy was approximately 1600 foot-pounds (220 kilogram-meters).

The first bullet produced small entrance and exit wounds. The second bullet made a small entry and a very large exit in the head.

The 6.5-millimeter Mannlicher-Carcano bullet, made by the Western Cartridge Company is approximately 30 mm. in length and 160 grains (10 grams) in weight. It has a full copper-jacket, a round nose and parallel edges. It has great stability.

Pierre A. Finck
PIERRE A. FINCK
Lt Colonel, MC, USA
Chief, Wound Ballistics Pathology Branch
Armed Forces Institute of Pathology
Washington, D.C. 20305

25